

SEMEN CHARACTERISTICS AND SPERMIOGRAM OF THE AFRICAN GREATER CANE RAT (*THRYONOMYS SWINDERIANUS*, TEMMINICK)

S. G. OLUKOLE^{1*}, M. O. OYEYEMI², B. O. OKE¹

¹Department of Veterinary Anatomy, Faculty of Veterinary Medicine, University of Ibadan, Ibadan, Nigeria

²Department of Veterinary Surgery and Reproduction, Faculty of Veterinary Medicine, University of Ibadan, Ibadan, Nigeria

ABSTRACT

Semen characteristics and spermatozoa morphological analysis were determined in twenty sexually matured domesticated African greater cane rats (*Thryonomys swinderianus*, Temminick). Semen was collected from the cane rats using the electroejaculation method followed by orchidectomy using open castration. The testis and epididymis were retrieved for sperm morphological studies. The semen of the rats was characteristically in coagulated form, opalescent in colour, gelatinously thick with no liquid fraction. The average volume of the ejaculates was 0.3 ± 0.04 ml. The total number of normal spermatozoa in the left and right testes was 308.5×10^9 .ml and 330.1×10^9 .ml, respectively. The percentage of abnormal spermatozoa observed in left and right testes were 9.8 % and 9.6 %, respectively. The percentages of abnormal spermatozoa observed in left and right epididymes were 10.6 % and 10.4 %, respectively. There was no significant difference ($P > 0.05$) between the percentages of abnormal spermatozoa found in both the left and right testes and epididymes. The spermatozoa head was ovoid in shape with its surface flat, whilst its acrosome lacked any hook. This absence of the acrosomal hook, typical for the sperm head of rodents, is therefore the first of its kind in the body of literature on the spermatozoa of rodents. It is, therefore, named the African greater cane rat "hookless sperm head" (by Olukole). This study presents base-line data on the semen characteristics and sperm morphology of the African greater cane rat and is expected to be useful in artificial insemination, comparative morphology of the spermatozoa of rodents and to improve breeding of the animal.

Key words: semen; spermatozoa; testis; epididymis; rat

INTRODUCTION

The African greater cane rat also known as the grasscutter (*Thryonomys swinderianus*) is a wild herbivorous rodent erroneously regarded by some as a larger version of the rat. It is related to the African porcupine, the brush tail porcupine as well as guinea pig, the chinchilla and the capybara of the South America (NRC, 1991). It is widely distributed in the African sub-region and exploited in most areas as a source of animal protein (Asibey and Addo, 2000). Being the most preferred bush meat in West Africa, including Nigeria, Togo, Benin, Ghana and Cote' d'Voire, it contributes

to both local and export earnings of most West African countries and is therefore hunted aggressively (GEPC, 1995).

Reproductive ability of a male had been reported to comprise the production of semen containing normal spermatozoa in adequate quality and quantity, in addition to the desire and ability to mate (Oyeyemi and Ubiogoro, 2005). The process of spermatogenesis is therefore a very productive and efficient mean of producing a large number of normal spermatozoa capable of fertilization. With millions of sperm produced per year, sperm morphological abnormalities do occur varying between 10 and 40 %

*Correspondence: E-mail: deborolukole@yahoo.com, sg.olukole@mail.ui.edu.ng
Samuel Gbadebo Olukole, Department of Veterinary Anatomy,
Faculty of Veterinary Medicine, University of Ibadan, Ibadan, Nigeria
Tel.: +2348033574752

Received: September 4, 2013
Accepted: January 14, 2014

(Harcourt, 1991). Spermatozoa are made up of three distinct segments: the head, mid-piece and tail. The head consists of the acrosomal cap and the post-acrosomal region. The tail is made up of the principal piece and the end or terminal piece. The sperm head contains the dense and compact DNA (Breed *et al.*, 2005).

Pioneering research reports on the African greater cane rat were concerned mainly of physiology, management, breeding and nutrition. The physiological, nutritional and pathological conditions of grasscutters are usually assessed using haematological and biochemical analysis of their blood (Awah and Nottidge, 1988; Fonweban and Njwe, 1990). Recent research reports on the anatomy of the African greater cane rat had been on the biometry of the testis and epididymis (Olukole *et al.*, 2009a); histology of the kidney (Olukole *et al.*, 2009b); gross anatomy of the male reproductive organs (Olukole *et al.*, 2010a) and histomorphometry of the testis and epididymis (Olukole and Obayemi, 2010). Also, the morphological characteristics of spermatozoa in bulls, boars and bucks had been described in the following reports: Oyeyemi *et al.* (2000); Oyeyemi and Ubiogoro, (2005) and Oyeyemi and Babalola (2006).

However, with the exception of the preliminary reports of Olukole *et al.* (2008) on sperm anatomy of the African greater cane rat; gonadosomatic index in relation to age (Adebayo *et al.*, 2009) and Olukole *et al.* (2010b) on sperm reserves in this rodent, reports on andrological studies of the animal are still scarce. This study, first of its kind, was therefore designed to characterize the semen and spermatozoa morphology of the domesticated adult African greater cane rat (*Thryonomys swinderianus*), thereby making available baseline data, which could be useful to improve breeding of this animal.

MATERIAL AND METHODS

Experimental Animals

Twenty domesticated adult male cane rats were used for the study. They were acquired from a commercial farm in Ogun State, Nigeria. Records on the age and feeding patterns of the animals were also obtained from the farm. The cane rats were kept at the Animal House, Faculty of Veterinary Medicine, University of Ibadan for 72 hours. They were kept on a daily ration of Guinea corn offal of about 0.5 kg per body weight supplemented with raw cassava (*Manihot species*).

Semen Collection

Semen was collected from the cane rats using the electroejaculation method, as described by Zemjanis (1977). The volume was determined

using a calibrated measuring cylinder, whilst the colour was determined by visual assessment. The rats were anaesthetized using chloroform and afterward sacrificed by cervical dislocation. Orchidectomy was performed by open castration method. A midline incision was made and the testicles were milked out of the incision site. The testicles were then exposed by incising the *tunica vaginalis*. Semen samples were thereafter collected from the *cauda epididymis* as described by Oyeyemi and Ubiogoro (2005).

Sperm count and motility assay

Sperm motility was assessed by the method described by Zemjanis (1977). The spermatozoa were counted by hemocytometer using the improved Neubauer (Deep 1/10 mm, LABART, Germany) chamber, as described by Pant and Srivastava (2003). A total of 400 spermatozoa from each rat were examined for morphological changes.

Morphological abnormalities and percentage viability assay

These were determined from a total count of 400 spermatozoa in smears prepared with Wells and Awa stains (0.2 g of Eosin and 0.6 g of Fast green dissolved in distilled water and ethanol at the ratio 2:1). Live/dead ratio was determined using 1 % Eosin and 5 % Nigrosin in 3 % sodium citrate dehydrate solution according to the method described by Oyeyemi and Babalola (2006).

Statistical Analysis

All data obtained were expressed as means with the standard error of mean using the GraphPad Prism version 4.00 for Windows, GraphPad Software. Analysis of variance was performed using two-way ANOVA and significance was reported at $P < 0.05$.

RESULTS

The semen characteristics and spermiogram of the cane rats used in this study are shown in Table 1. The semen was characteristically in coagulated form, opalescent in colour, gelatinously thick with no liquid fraction. The average volume of the ejaculate was 0.3 ± 0.04 ml. The sperm head was ovoid in shape with its surface flat, whilst its acrosome lacked any hook (Fig. 1). Normal spermatozoa of the adult domesticated cane rat, (making up of about 78 % of the total number of spermatozoa in one milliliter per ejaculate) are shown in Fig. 1. The mean progressive motility of spermatozoa and mean percentage of live spermatozoa for the cane rats were 73 ± 3.35 % and 95 ± 1.16 %, respectively. The mean total sperm count of the ejaculate

Table 1: Characteristics of spermatozoa of the domesticated adult African greater cane rat

Characteristics	Value/ Description
Colour	Opalescent
Volume (ml)	0.3 ± 0.04
Progressive Motility (%)	73 ± 3.35
Percentage live spermatozoa	95 ± 1.16
Total Sperm Count (x10 ⁹ .ml)	136.10 ± 9.15
Primary abnormality (%)	3.9 ± 1.02 ^a
Secondary abnormality (%)	7.9 ± 1.43 ^b
Tertiary abnormality (%)	11.2 ± 1.70 ^c

Means with different superscripts are significantly different (P< 0.05).

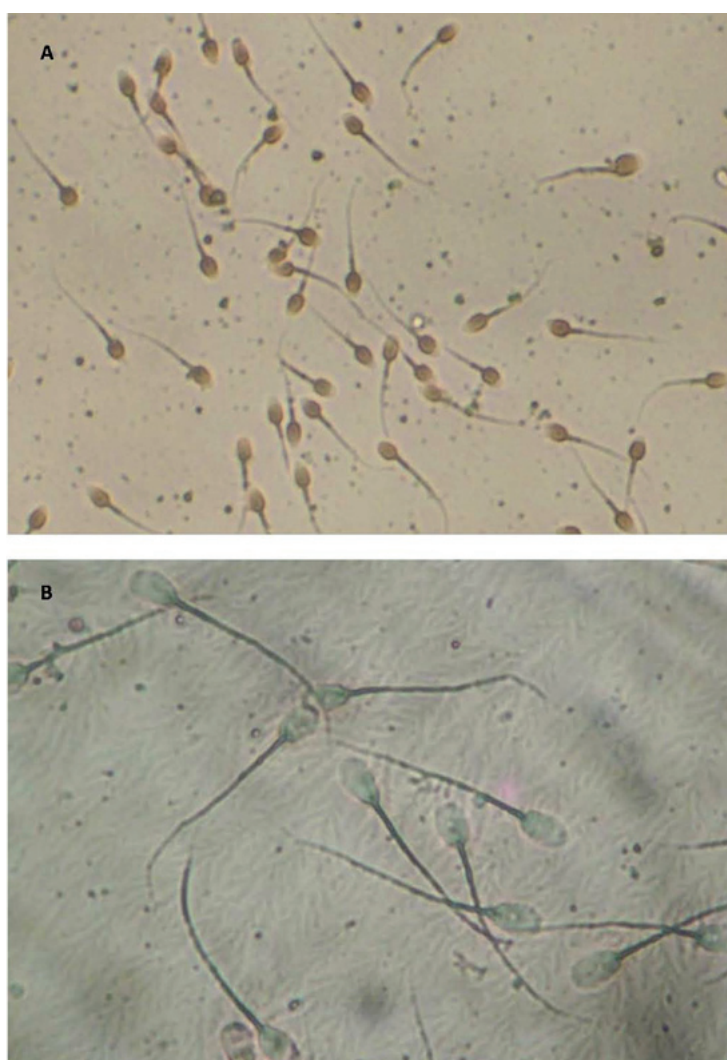


Fig. 1: Photomicrograph of the spermatozoa of the African greater cane rat (*Thryonomys swinderianus*, Temminck). A: Epididymal spermatozoa (magnification: x400); B: Testicular spermatozoa (Magnification: X1000), Eosin-Nigrosin. Note the absence of acrosomal hook on spermatozoa head

Table 2: Mean values of morphological characteristics of spermatozoa in the testis and epididymis of the domesticated adult African greater cane rat (in ml)

Morphological Characteristics	Testis	Caput	Corpus	Cauda	Epididymal mean
Tailless Head (L)	4.0	3.9	4.5	4.2	4.2
Tailless Head (R)	4.7	3.7	4.2	4.1	4.0
Headless Tail (L)	3.5	4.1	5.2	4.3	4.5
Headless Tail (R)	3.9	4.4	4.9	4.4	4.6
Rudimentary Tail (L)	1.3	1.2	1.6	1.7	1.5
Rudimentary Tail (R)	1.9	1.7	1.2	1.4	1.4
Bent Tail (L)	5.2	7.0	7.2	6.9	7.0
Bent Tail (R)	5.2	7.5	7.0	6.2	6.9
Curved Tail (L)	6.0	6.1	6.7	6.3	6.4
Curved Tail (R)	6.3	6.9	5.0	6.5	6.1
Curved Mid-piece (L)	5.8	6.7	7.2	7.4	7.1
Curved Mid-piece (R)	5.5	6.4	7.3	6.2	6.6
Bent Mid-piece (L)	6.5	7.8	8.4	8.1	8.1
Bent Mid-piece (R)	6.1	8.7	7.2	7.3	7.7
Coiled Tail (L)	0.5	0.8	1.3	1.1	1.1
Coiled Tail (R)	0.9	1.3	1.5	1.4	1.4
Looped Tail (L)	0.9	1.5	1.7	1.4	1.5
Looped Tail (R)	0.5	1.2	1.4	1.1	1.2
Total Abnormal Sperm Cells (L)	33.7	39.1	43.8	41.4	41.4
Total Abnormal Sperm Cells (R)	35.0	41.8	39.7	38.5	40.0
% Abnormal Sperm Cells (L)	9.8	10.6	11.1	10.1	10.6
% Abnormal Sperm Cells (R)	9.6	10.9	10.7	9.6	10.4
Total Normal Sperm Cells (L)	308.5	331.3*	351.0	370.1*	350.8
Total Normal Sperm Cells (R)	330.1	341.8*	330.6	363.3*	345.2
% Normal Sperm Cells (L)	90.2	89.4	88.9	89.9	89.4
% Normal Sperm Cells (R)	90.4	89.1	89.3	90.4	89.6
Total Sperm Cells (L)	342.2	370.4*	394.8*	411.5*	392.2
Total Sperm Cells (R)	365.1	383.6	370.3	401.8	385.2

L: Left; R: Right.

* Significantly different ($P < 0.05$).

for the cane rats was $136.10 \pm 9.15 \times 10^9$.ml. The incidence of the spermatozoa with primary abnormalities was 3.9 % whilst those of secondary and tertiary abnormalities were 7.9 % and 11.2 %, respectively (Table 1) with significant ($P < 0.05$) differences.

The results of morphology of spermatozoa

isolated from the testis and different segments of the epididymides are presented in table 2. The total numbers of normal spermatozoa in the left and right testes were 308.5×10^9 .ml and 330.1×10^9 .ml, respectively. The percentage of abnormal spermatozoa observed in left and right testes were 9.8 % and 9.6 %, respectively. The percentages of abnormal

spermatozoa observed in left and right epididymes were 10.6 % and 10.4 %, respectively. There was no significant difference ($P>0.05$) between the percentages of abnormal spermatozoa found in both the left and right testes and epididymes. Spermatozoa with coiled tail and looped tail were the least encountered abnormal cells observed in the left and right testes and epididymes respectively (Table 2), whilst spermatozoa with bent mid-piece were the most frequently encountered abnormal cells in the left and right testes and epididymes. There were significant differences ($P<0.05$) in the number of normal spermatozoa found in the caput and cauda epididymis for both the right and left (Table 2). The testis, when compared with the epididymis, had lesser number of abnormal spermatozoa, whilst the cauda epididymis manifested the least number of spermatozoa in comparison with the caput and corpus epididymis (Table 2). Nevertheless, there were no significant differences ($P>0.05$) between these numerical observations.

DISCUSSION

The characteristic opalescent, coagulated and gelatinous ejaculated semen of the cane rats used in the study is similar to the ejaculated semen of the laboratory rat; mouse and guinea pig obtained using the electro-ejaculator method (Kishikawa *et al.*, 1999). The characteristics of the ejaculate obtained in the study using the electroejaculation method agree with the findings of Oyeyemi *et al.* (2000) on the West-African Dwarf (WAD) buck. Nevertheless, the average volume of semen obtained in the study was however lower than reported in the WAD buck by Oyeyemi and Babalola (2006). The coagulation of the semen in some rodents has been reported to be due to the secretion from the coagulating glands or anterior lobe of the prostate, which contains an enzyme called vesiculase (Oyeyemi *et al.*, 2000). However, Oke and Aire (1996) reported that the coagulating gland of the African giant rat is considered to be part of the seminal vesicle, rather than the prostate. Thus, the coagulating protein and enzyme appear to be derived from the structures having closer anatomical relationship than in the rat or guinea pig.

The motility and percentage of live spermatozoa obtained in the study are high enough to assure fertility. Motility of spermatozoa and percentage of live spermatozoa at the time of collection are commonly used as a measure of the fertilizing ability of sperm (Oyeyemi and Ubiogoro, (2005). The shape of sperm head of the African greater cane rat like those of most mammals is flat and oval. This is in

conformity with previous reports on spermatozoa morphology in mammals (Villalpando *et al.*, 2000; Breed *et al.*, 2005; Oyeyemi and Babalola, 2006). The absence of an acrosome hook on the head of the spermatozoa of the African greater cane rat discriminates it from sperm cells of other rodents. The rat, Golden hamster (Blandau, 1951; Leblond *et al.*, 1952), Volcano mouse (Villalpando *et al.*, 2000) and approximately 11 other subfamilies (~151 species) of rodents studied by Breed *et al.* (2005) all have a sperm head that folds back onto itself producing a “hook”-like shape referred to as the apical hook. This report on the absence of acrosomal hook typical of the sperm head of rodents is, therefore, the first of its kind in the literature on the spermatozoa of rodents. It is thus named the African greater cane rat “hookless sperm head” (by Olukole).

Also, the presence of abnormal forms of spermatozoa in this study is consistent with the report of Moss *et al.* (1979), that a number of abnormal forms of spermatozoa are normally encountered in all ejaculates. Only when they are present in large numbers, they are associated with impaired fertility. Cohen (1973) has proposed that the incidence of abnormal sperm is simply an error in the process of spermatogenesis. In contrast, Barker *et al.* (1988, 1989) suggests that abnormal sperm were purposefully created and were never meant to partake in the act of fertilizing an ovum, but were constructed for the purpose of sperm competition and to hinder other male's sperm from achieving fertilization in cases when a female mates with multiple males during the oestrus.

The sperm morphological characteristics observed in the study are similar to those described by Oyeyemi and Babalola (2006) in the bull. The low level of the spermatozoa morphological abnormalities observed in the study indicates that the cane rats were fertile. The number of the spermatozoa with head abnormalities observed in the study in both the testis and epididymis put together further underscores of the potential breeding soundness of the cane rats used for this study. The higher values of secondary (bent mid-piece, curved mid-piece, bent tail and looped tail) and tertiary (tailless head, headless tail) sperm abnormalities obtained in the study, compared to primary abnormalities, are in agreement with the previous report (Oyeyemi and Ubiogoro, 2005) on the spermatozoa of mammals of sound breeding potentials. Secondary abnormalities have been reported to be due to changes that take place in the excurrent duct of the testis, whilst primary abnormalities are generated during spermatogenesis. Tertiary abnormalities are due to handling techniques like cold or heat shock, osmotic effects, toxicity of stains or changes in pH during collection and processing of semen (Moss *et al.*, 1979).

CONCLUSION

This study has shown that the sperm head of the African greater cane rat, unlike a typical rodent, lacks acrosomal hook. It also presents baseline data on the semen characteristics and sperm morphology of the animal, which hitherto had not been described yet. The findings of this work, therefore, are expected to be useful in artificial insemination, comparative morphology of the spermatozoa of rodents and to improve breeding of the animal.

ACKNOWLEDGEMENT

The authors are thankful to the technical staff of the Department of Surgery and Reproduction, University of Ibadan for the technical support rendered during the course of this work.

REFERENCES

- ADEBAYO, A. O. – OKE, B. O. – AKINLOYE, A. K. 2009. Characterizing the Gonadosomatic Index and Its Relationship with Age in Greater Cane Rat (*Thryonomys swinderianus*, Temminck). *Journal of Veterinary Anatomy*, vol. 2 (2), 2009, p. 53-59.
- ASIBEY, E. O. A. – ADDO, P. G. 2000. The grasscutter, a promising animal for meat production. In: Turnham D. (ed.), African perspective practices and policies supporting sustainable development, Scandinavian College Seminar, Denmark, in association with Weaver Press, Harare, Zimbabwe. 2000, p. 23-45.
- AWAH, J. N. – NOTTIDGE, H. O. 1988. Serum biochemical parameters in clinically healthy dogs in Ibadan. *Tropical Veterinarian*, vol. 16 (3-4), 1988, p. 123-129.
- BARKER, R. R. – BELLIS, M. A. 1988. „Kamikaze“ sperm in mammals? *Animal Behavior*, vol. 36 (3), 1988, p. 936-939.
- BARKER, R. R. – BELLIS, M. A. 1989. Elaboration of the kamikaze sperm hypothesis. *Animal Behavior*, vol. 37 (5), 1989, p. 865-867.
- BLANDAU, R. J. 1951. Observations on the morphology of rat spermatozoa mounted in media of different refractive indices and examined with the phase microscope. *The Anatomical Record*, vol. 109, 1951, p. 271-275.
- BREED, W. G. 2005. Evolution of the spermatozoon in muroid rodents. *Journal of Morphology*, vol. 265 (3), 2005, p. 271-290.
- COHEN, J. 1973. Crossovers, sperm redundancy, and their close association. *Heredity*, vol. 31, 1973, p. 408-413.
- FONWEBAN, J. N. – NJWE, R. M. 1980. Feed utilization and live weight gain by the African giant rat (*Cricetomys gambianus* Waterhouse) at Dschang in Cameroon. *Tropicicultura*, vol. 8, 1980, p. 118.
- GHANA ENVIRONMENTAL PROTECTION AND CONTROL (GEPC) 1995. In: Addo, P. G. Detection of mating, pregnancy and imminent parturition in the grasscutter (*Thryonomis swinderianus*). *Livestock Research for Rural Development*, vol. 14 (4), 1995, p. 8.
- HARCOURT, A. H. 1991. Sperm competition and the evolution of nonfertilizing sperm in mammals. *Evolution*, vol. 45, 1991, p. 314-328.
- KISHIKAWA, H. H. – TATENO, B. – YANAGIMACHI, R. 1999. Fertility of mouse spermatozoa retrieved from cadavers and maintained at 4°C. *Journal of Reproduction and Fertility*, vol. 116 (2), 1999, p. 217-222.
- LEBLOND, C. P. – CLERMONT, Y. 1952. Spermiogenesis of rat, mouse, hamster and guinea pig as revealed by the periodic acid-fuchsin sulfurous acid technique. *American Journal of Anatomy*, vol. 90 (2), 1952, p. 167-215.
- MOSS, J. A. – MELROSE, D. R. – REED, H. C. B. – VANDEPLASSCHE, M. 1979. Semen and artificial insemination. In: Fertility and infertility in domestic animals. Laing, J. A. (eds) 3rd, London, Bailliere Tindal, 1979, p. 57.
- NATIONAL RESEARCH COUNCIL (NRC). 1991. Microlivestock: Little known small animals with promising economic future. National Academy Press, Washington D.C., 1991, p. 449.
- OKE, B. O. – AIRE, T. A. 1996. The coagulating gland of the African giant rat (*Cricetomys gambianus*, Waterhouse). *Tropical Veterinarian*, vol. 14, 1996, p. 23-29.
- OLUKOLE S. G. – OBAYEMI T. E. 2010. Histomorphometry of the Testes and Epididymis in the domesticated adult African great cane rat (*Thryonomys swinderianus*). *International Journal of Morphology*, vol. 28 (4), 2010, p. 1251-1254.
- OLUKOLE, S. G. 2009b. Morphometric analysis of the kidneys of the adult domesticated African great cane rat (*Thryonomys swinderianus*). *European Journal of Anatomy*, vol. 13 (3), 2009, p. 117-120.
- OLUKOLE, S. G. – OYEYEMI, M. O. – OKE, B. O. 2008. Sperm Anatomy of the Domesticated Grasscutter (*Thryonomys swinderianus*). Proceedings of the 45th Annual Congress of the Nigerian Veterinary Medical Association (NVMA), 2008, p. 50-52.
- OLUKOLE, S. G. – OYEYEMI, M. O. – OKE, B. O. 2009a. Biometrical Observations on the Testes and Epididymis of the Domesticated Adult African Great Cane Rat (*Thryonomys swinderianus*). *European Journal of Anatomy*, vol. 13 (2), 2009, p. 71-75.
- OLUKOLE, S. G. – OYEYEMI, M. O. – OKE, B. O.

- 2010a. Gross Anatomy of the male reproductive organs of the domesticated grasscutter (*Thryonomys swinderianus*, Temminick). Proceedings of the 35th Annual Conference of the Nigerian Society for Animal Production (NSAP) held in the University of Ibadan, Ibadan, Nigeria, 2010, p. 268-271.
- OLUKOLE, S. G. – OYEYEMI, M. O. – OKE, B. O. 2010b. Gonadal and extragonadal sperm reserves of the domesticated adult African greater cane rat (*Thryonomys swinderianus*). *Reproductive Biology*, vol. 10 (2), 2010, p. 55-158.
- OYEYEMI, M. O. – UBIOGORO, O. 2005. Spermogram and morphological characteristics in testicular and epididymal spermatozoa of large boar in Nigeria. *International Journal of Morphology*, vol. 23 (3), 2005, p. 235-239.
- OYEYEMI, M. O. – AKUSU, M. O. – OLA-DAVIES, O. E. 2000. Effect of successive ejaculations on the spermogram of West African Dwarf goats (*Capra hircus*). *Veterinarski Arhiv*, vol. 70 (4), 2000, p. 215-222.
- OYEYEMI, M. O. – BABALOLA, T. E. 2006. Testicular parameters and morphological characteristics of testicular and epididymal spermatozoa of white Fulani bulls in Nigeria. *International Journal of Morphology*, vol. 24 (2), 2006, p. 175-180.
- PANT, N. – SRIVASTAVA, S. P. 2003. Testicular and spermatotoxic effect of quinaphos in rats. *Journal of Applied Toxicology*, vol. 23 (4), 2003, p. 271-274.
- VILLALPANDO, I. – VILLAFAN-MONROY, H. – AGUAYO, D. – ZEPEDA-RODRIGUEZ, A. – ESPITIA, H. G. – CHAVEZ-OLIVARES, A. 2000. Ultrastructure and motility of the caudal epididymis spermatozoa from the Volcano mouse (*Neotomodon alstoni alstoni Merriam*, 1898). *The Journal of Experimental Zoology*, vol. 287 (4), 2000, p. 316-326.
- ZEMJANIS, R. 1977. Diagnostic and therapeutic technique in animal reproduction. Baltimore, Williams and Wilkins Company, 1977, p. 46-49.